

## Mutton-Fat Keratic Precipitates (KP)

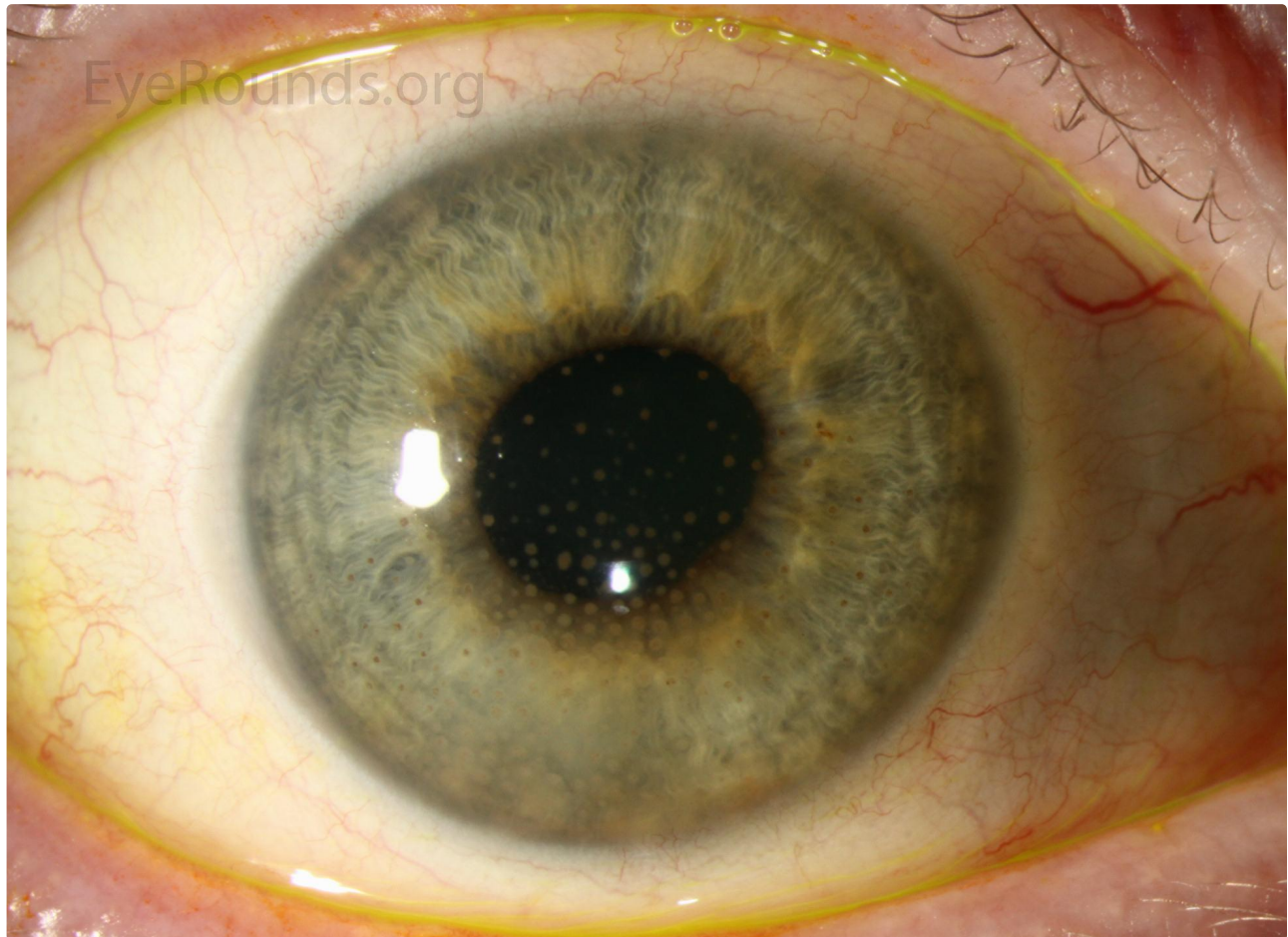
Category(ies): Cornea, Uveitis

Contributor: [Lucas Lenci, MD](#)

Photographer: Carol, Chan, MD

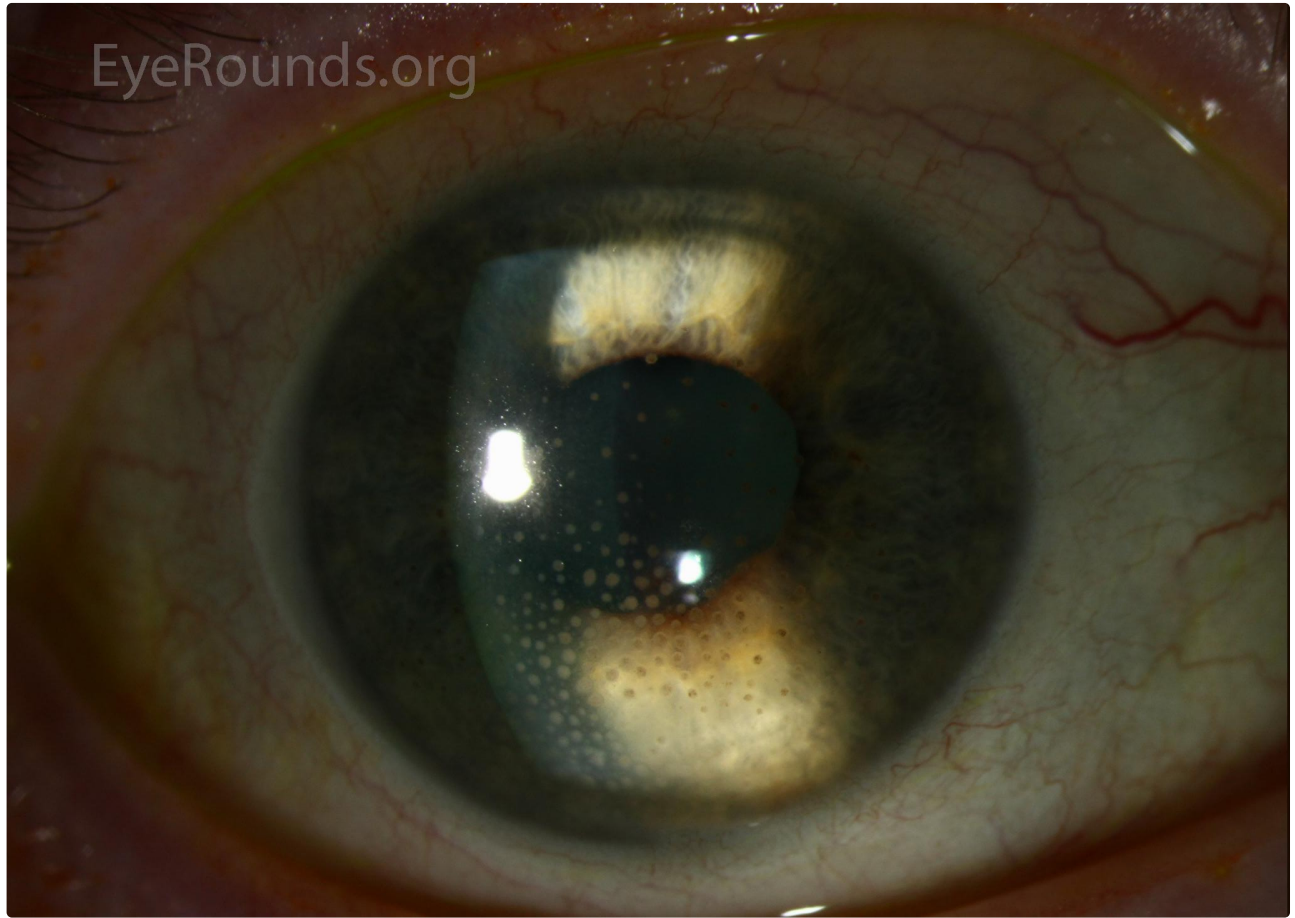


This is a 51-year-old female that presented with severe ocular pain and photophobia. She presented acutely and had evidence of mutton-fat keratic precipitates (KP) on exam. She was later diagnosed with sarcoidosis. KP are collections of inflammatory cells on the corneal endothelium. When these coalesce and become large with a yellowish color, they are described as mutton-fat KP. These are typically associated with granulomatous inflammation.



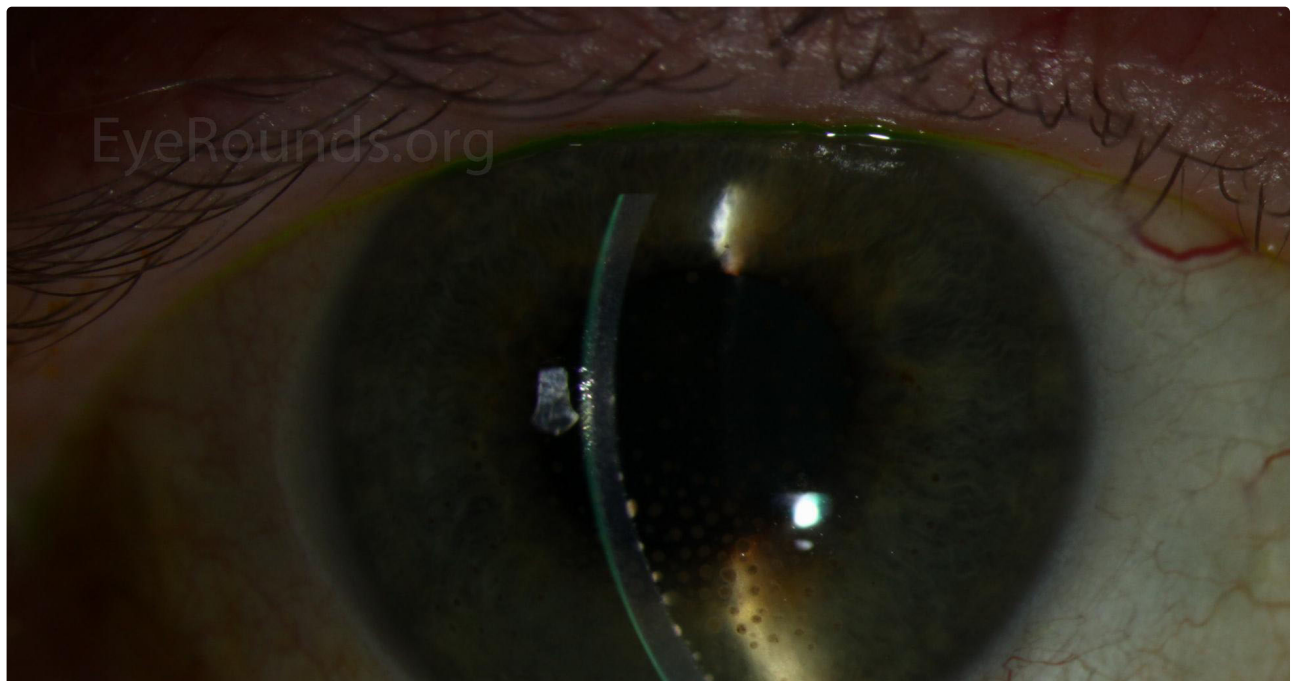
[Enlarge](#)

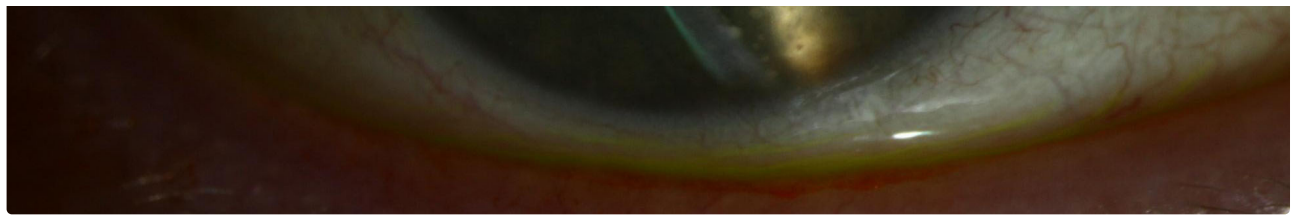
[Download](#)



[Enlarge](#)

[Download](#)





 [Enlarge](#)

 [Download](#)

### Image Permissions:



Ophthalmic Atlas Images by [EyeRounds.org](http://EyeRounds.org), [The University of Iowa](http://The University of Iowa) are licensed under a [Creative Commons Attribution-NonCommercial-NoDerivs 3.0 Unported License](https://creativecommons.org/licenses/by-nc-nd/3.0/).

### Address

University of Iowa  
Roy J. and Lucille A. Carver College  
of Medicine  
Department of Ophthalmology and  
Visual Sciences  
200 Hawkins Drive  
Iowa City, IA 52242

[Support Us](#)

### Legal

Copyright © 2019 The University of  
Iowa. All Rights Reserved  
[Report an issue with this page](#)  
[Web Privacy Policy](#) |  
[Nondiscrimination Statement](#)

### Related Links

[Cataract Surgery for Greenhorns](#)  
[EyeTransillumination](#)  
[Gonioscopy.org](http://Gonioscopy.org)  
[Iowa Glaucoma Curriculum](#)  
[Iowa Wet Lab](#)  
[Patient Information](#)  
[Stone Rounds](#)  
[The Best Hits Bookshelf](#)

### EyeRounds Social Media

Follow



Receive notification of new cases,  
[sign up here](#)  
[Contact Us](#)  
[Submit a Suggestion](#)